

Noncompliance Unilateral Maxillary Molar Distalization: A Three-Dimensional Tooth Movement Analysis

Anestis Mavropoulos^a; Korkmaz Sayinsu^b; Ferdi Allaf^c; Stavros Kiliaridis^d;
Moschos A. Papadopoulos^e; Ahmet Ozlem Keles^f

Abstract: The aim of this prospective study was the three-dimensional (3-D) analysis of tooth movements after unilateral upper molar distalization by means of a noncompliance intraoral appliance, the Keles slider. This appliance exerts a distalizing force of 150 g at approximately the level of the center of resistance of the upper first molar. Twelve patients (six girls and six boys with a mean age of 13.1 years) with a unilateral Class II molar relationship participated in the study. Dental casts were taken immediately before placement and after removal of the appliance. The casts were digitized using a 3-D surface laser scanner and superimposed on a predefined area of the palate. The average unilateral upper first molar distal movement was 3.1 mm (range: 2.4 to 5.3 mm). Anchorage loss was expressed by a 2.1 mm (range: 0.8 to 3.8 mm) proclination of the central incisors and a 6.1° mesial inclination of the ipsilateral first premolar (range: 1.7° to 12.3°). There was approximately 1 mm of midline deviation toward the contralateral side and a 1.6 mm (range: 0.8 to 2.3 mm) buccal displacement of the contralateral first premolar. A substantial variation was observed among patients. Noncompliance unilateral upper molar distalization was an efficient treatment approach. There was, however, a substantial anchorage loss. Case selection is strongly recommended because significant anterior crowding, ectopic canines, or spacing can lead to significant anchorage loss. (*Angle Orthod* 2006;76:382–387.)

Key Words: Class II malocclusion; Noncompliance treatment; Unilateral distalization; Three-dimensional cast superimposition; Keles slider

INTRODUCTION

For many years asymmetric headgear force application was used routinely for the unilateral distalization of maxillary molars.^{1–3} It has, however, been shown

that such a force delivery system unavoidably contains a lateral component, which can result in a posterior crossbite.⁴ Another serious disadvantage of headgear treatment is the need of patient compliance, which is sometimes difficult or impossible to obtain.^{5–7}

^a Lecturer, Department of Orthodontics, University of Geneva, Geneva, Switzerland.

^b Assistant Professor, Department of Orthodontics, Yeditepe University, Istanbul, Turkey.

^c Research Fellow, Department of Orthodontics, Yeditepe University, Istanbul, Turkey.

^d Professor and Department Chair, Department of Orthodontics, University of Geneva, Geneva, Switzerland.

^e Assistant Professor, Department of Orthodontics, School of Dentistry, Aristotle University of Thessaloniki, Thessaloniki, Greece.

^f Research Scientist, Department of Cytokine Biology, The Forsyth Institute, Boston, Mass.

Corresponding author: Dr. Anestis Mavropoulos, Department of Orthodontics, University of Geneva, Barthelémy-Menn 19 Geneva, Geneva 1205, Switzerland (e-mail: anestis.mavropoulos@medecine.unige.ch)

Accepted: June 2005. Submitted: May 2005.

© 2006 by The EH Angle Education and Research Foundation, Inc.

Over recent years, several noncompliance methods to move molars distally have gained popularity.⁸ A number of previous investigations evaluated the effectiveness of these treatment modalities on lateral cephalometric radiographs.^{9–13} They all reached the conclusion that the distal movement of the upper molars is accompanied by distal tipping and a considerable loss of anchorage with mesial displacement and tipping of the anterior anchorage unit.¹⁴ There are a few case reports but yet no conclusive evidence on the tooth movements that occur when the same appliances are used unilaterally after some modification.^{15,16}

It is extremely difficult to accurately evaluate unilateral tooth movements on cephalometric radiographs because both sides are projected simultaneously on the midsagittal plane. Recent advances in the application of three-dimensional (3-D) imaging for dental purposes have made possible a more accurate as-

TABLE 1. Detailed Information for All Patients Participating in This Study

Patient	Pretreatment Age (y)	Treatment Duration (wk)	Presence of Upper Second Molars
1	14.0	16.0	+
2	14.1	15.5	+
3	12.4	15.5	-
4	14.1	20.0	+
5	13.7	18.5	+
6	10.8	16.5	+
7	13.8	19.0	+
8	13.5	17.5	+
9	10.7	19.5	+
10	14.2	21.5	+
11	13.5	16.0	+
12	12.5	14.5	-

assessment of tooth positional changes on dental casts.¹⁷⁻²⁰ The reliability of generating 3-D dental images using surface laser scanners has been investigated, and it has been demonstrated that these devices have great research potential in orthodontics because of their ability to yield accurate and reproducible data. The assessment of differences between direct measurements made on dental casts and those made on computer reconstructed images generated by surface laser scanners showed that these devices are highly accurate for dental cast analysis.²¹⁻²³

The aim of this prospective study was the 3-D analysis of tooth movements after the noncompliance unilateral distalization of the maxillary molars by means of the Keles slider. By incorporating the whole contralateral side in the anchorage unit, unilateral distalization could theoretically be accomplished with less anchorage loss than with bilateral distalization.

MATERIALS AND METHODS

Subjects

Twelve patients (six girls and six boys with a mean age of 13.1 years) with unilateral Class II molar relationship were treated with this appliance during the first phase of their overall orthodontic treatment. In all but two cases, upper second molars had already erupted. Class I molar relationship was achieved on both sides in all cases during an average treatment period of 17.5 weeks (Table 1). Maxillary dental casts were taken immediately before placement and after removal of the appliance.

Intraoral appliance

The Keles slider (Patent no: US 6,626,665 B1) was modified for unilateral use. In summary, the appliance consisted of an active unit and an anchorage unit^{22,23}

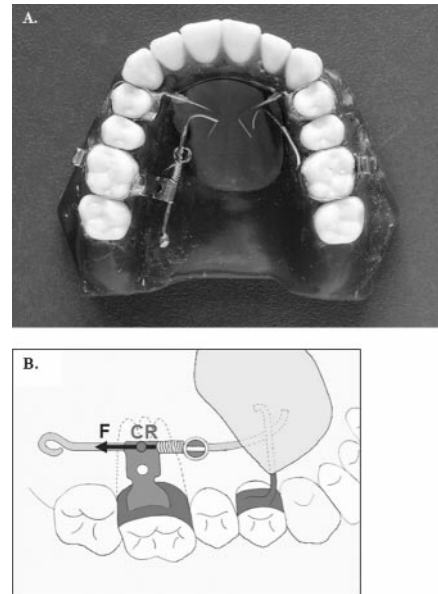


FIGURE 1. (A) Occlusal view of the intraoral noncompliance appliance used in this investigation for the distalization of the upper molars. (B) Diagrammatic representation of the point of force application (F, force; CR, center of resistance).

(Figure 1A). The molar to be distalized was banded, and a tube (Dentaurum 607-301-00, Ispringen, Germany) was soldered parallel to the occlusal plane on the palatal side of the band at the level of the molar's center of resistance (Figure 1B). A heavy Ni-Ti coil spring (Leone C1214, Firenze, Italy) was compressed by means of a screw (3M Unitek, Gurin lock, Monrovia, Calif) between this tube and the anchorage unit, which was a modified Nance button attached to bands on the first premolars and the contralateral molar.

This configuration resulted in the molar receiving an initial force of approximately 150 g with a force vector located very close to the level of its center of resistance. Patients were seen every month, and the screw was reactivated every 2 months with a special wrench (3M Unitek, Gurin lock wrench). After the removal of the appliance, the coil spring was removed, the screw positioned mesially to the tube, the wires connecting the Nance button to the premolars were cut off and their bands were removed. This way the same Nance appliance was used to stabilize the molars until after the retraction of the canines.

Three-dimensional cast superimposition and analysis

The method used for the 3-D analysis of tooth movements has been described previously and validated.²³ In summary, all casts were digitized using a 3-D surface laser scanner (Laserscan 3-D Pro, Willytec GmbH, Gräfelfing, Germany) (Figure 2A). The ob-

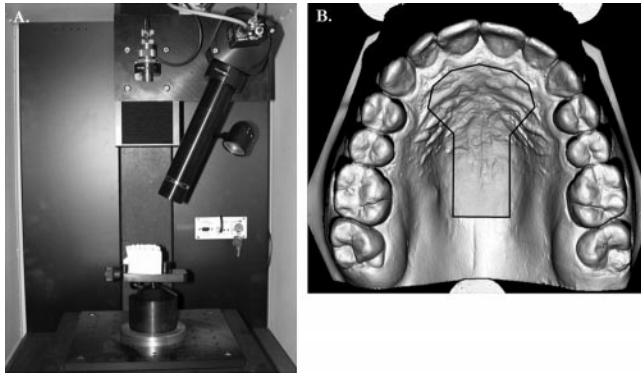


FIGURE 2. (A) The three-dimensional (3-D) laser scanner assembly. (B) An example of a cast occlusal surface as seen on screen after having been three-dimensionally scanned using this apparatus. The delineated area corresponds to the region where the 3-D superimposition was performed in this study. (From Mavropoulos et al 2005,²³ with permission of Elsevier Health Sciences).

tained holograms were then transferred through a video acquisition system to a personal computer (Siemens Expert, Siemens AG, Munich, Germany), controlled by the SCAN-3-D software (Willytec GmbH). The pre- and posttreatment 3-D images were superimposed on a predefined area in the palate (Figure 2B). This area of superimposition included the anterior part of the palate comprising the palatal rugae and a zone in the palate along the midline raphe.

The result was a new hologram, the product of the fusion of the two initial holograms after their superimposition. To make the results clinically more relevant, tooth movements were measured along the axis where they actually took place, ie, the lateral arch segments. The vertical changes were measured by placing the cursor over the mesial fossa of the first premolar and over the central fossa of the first molar to register the differences in the z-axis.

Error of the method

The whole measurement procedure was repeated 2 to 4 weeks after the initial measurements. The error of both methods was calculated according to the formula: $Se = \sqrt{\sum d^2 / 2n}$, where $\sum d^2$ is the sum of the squared differences between pairs of recordings and n is the number of duplicate measurements.²⁴ It did not exceed 0.25 mm and 1.6° for the linear and angular measurements, respectively.

RESULTS

The software used to measure the data obtained from the 3-D cast digitization gave us the possibility to construct the mean tracing combining the data from the entire sample (Figure 3). The total and effective sagittal movements of the first molars, first premolars,

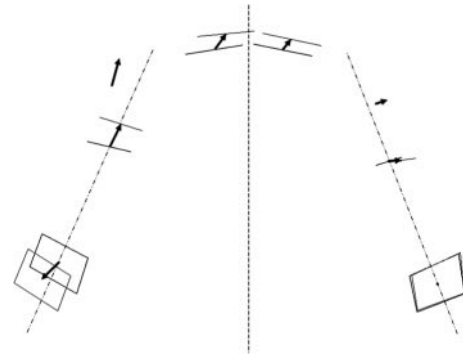


FIGURE 3. Mean tracing. The arrows show the direction and magnitude of the tooth movements after the use of the unilateral distalizing appliance. Only the movements of the first molars, first premolars, canines and central incisors are shown.

canines, and incisors, as well as the vertical, lateral, tipping, and rotational changes are shown in Table 2. The distal movement of the first molars was a mean of 3.1 mm. Individual differences were significant with effective distal movement ranging from 2.4 to 5.3 mm. The distalization of the upper first molars was accompanied by minimum distal tipping (4.0°), buccal displacement (1.3 mm), intrusion (1.1 mm), and mesial rotation (5.1°).

Loss of anchorage was demonstrated on both the ipsilateral and the contralateral sides. The ipsilateral first premolar moved mesially 3.2 mm. This was accompanied by mesial tipping (6.1°), negligible palatal displacement (0.2 mm), extrusion (0.6 mm), and mesial rotation (4.5°). Individual variation was also evident with the mesial movement ranging from 2.4 to 5.3 mm. The ipsilateral canine, as part of the anterior anchorage unit, was also affected. It moved a mean of 3.5 mm mesially and 0.6 mm buccally. The central incisors were proclined a mean of 1.7 mm (range 0.8 to 3.5 mm). It is interesting to note that the upper dental midline moved toward the contralateral side by 1.2 mm on average.

The contralateral side did not remain unaffected. The contralateral canine moved buccally (1.3 mm), whereas the first premolar moved slightly distally (0.4 mm), buccally (1.6 mm), and rotated distally (3.3°). The contralateral first molar was not affected apart from a slight distal rotation of 1.0° on average. It appeared that the whole anterior anchorage unit was rotated toward the contralateral side with the contralateral first molar as the center of rotation.

DISCUSSION

The intraoral appliance used in this study was successfully used for the unilateral distalization of maxillary first molars into a Class I molar relationship in all cases. In all but two cases, the second molars had

TABLE 2. Evaluation of Movement of All Teeth Under Investigation After the Use of the Noncompliance Molar-distalizing Intraoral Appliance. Values are Given as Mean ± SD (Range in parentheses)^a

	Total Movement	Effective (Mesiodistal) Movement	Mesiodistal Tipping	Vertical Movement	Lateral Movement	Rotation
Active unit						
First molar	3.7 ± 1.0 mm (2.5 to 5.6)	-3.1 ± 0.9 mm (-2.4 to -5.3)	-4.0 ± 3.4° (-9.9 to -0.4)	-1.1 ± 0.9 mm (-2.3 to +0.5)	+1.3 ± 1.6 mm (-1.7 to +3.1)	+5.1 ± 4.7° (+0.1 to +12.4)
Anchorage unit (ipsilateral side)						
First premolar	3.4 ± 1.2 mm (1.2 to 5.7)	+3.2 ± 1.1 mm (+2.4 to +5.3)	+6.1 ± 4.2° (+1.7 to 12.3)	+0.6 ± 0.8 mm (-0.6 to +1.7)	-0.2 ± 1.3 mm (-2.6 to +2.5)	+4.5 ± 4.7° (-3.8 to +12.5)
Canine	3.7 ± 1.3 mm (1.9 to 5.8)	+3.5 ± 1.1 mm (+1.8 to +5.3)	—	—	+0.6 ± 1.1 mm (-0.9 to +2.8)	—
Midline	2.1 ± 1.1 mm (0.8 to 3.8)	+1.7 ± 0.8 mm (+0.8 to +3.5)	—	—	1.2* ± 1.0 mm (0.0 to 2.9)	—
Anchorage unit (contralateral side)						
Canine	1.5 ± 0.6 mm (0.5 to 2.1)	-0.1 ± 0.7 mm (-1.4 to +0.5)	—	—	+1.3 ± 0.6 mm (+0.4 to +2.0)	—
First premolar	1.6 ± 0.6 mm (0.8 to 2.3)	-0.4 ± 0.5 mm (-1.2 to +0.3)	+0.5 ± 1.9° (-1.6 to +3.1)	+0.5 ± 0.6 mm (-0.5 to +1.4)	+1.6 ± 0.6 mm (+0.8 to +2.3)	-3.3 ± 7.6° (-12.1 to +9.7)
First molar	0.2 ± 0.1 mm (0.1 to 0.3)	0.0 ± 0.1 mm (-0.1 to +0.0)	+0.1 ± 0.6° (-0.7 to +0.8)	0.0 ± 0.3 mm (-0.6 to +0.6)	+0.1 ± 0.1 mm (0.0 to +0.3)	-1.0 ± 1.2° (-2.6 to +1.0)

^a +/- signs: + for mesial, buccal, or extrusive, - for distal, palatal, or intrusive movement; R, right; L, left; * Toward the contralateral side.

also erupted. Distal movement of both first and second upper molars in full occlusion is considered extremely difficult to accomplish without patient cooperation or substantial anchorage loss.¹⁴

After the first phase distalization treatment, the Keles slider was converted to a sort of big Nance appliance to stabilize the molars until the retraction of the canines was accomplished. This had the purpose of encouraging the spontaneous distal drift of the first and second premolars taking advantage of the transeptal fiber pull to maintain the distal position of molars. Approximately half of the space created between the maxillary first molar and first premolar was because of the distal movement of the crown of the first molar. The other half represents the anchorage loss. Significant individual variation was observed. The upper midline was displaced toward the contralateral side and both the contralateral canine and the first premolar were buccally displaced.

Our findings confirm the results of previous studies using similar noncompliance distalizing modalities with Ni-Ti coil springs,^{9-11,23,25-27} although their samples consisted of patients with either unerupted⁹ or both erupted and unerupted^{10,25,26} second molars. Only in three of these studies had the upper second molars fully erupted in all cases.^{9,23,27} However, the influence of the second molars on the distal movement of the first molars remains a matter of controversy. It has been reported that the presence of second molars increases the duration of treatment time,²⁵ produces more tipping,⁹ and more anchorage loss.²⁸ It has also been

suggested that the eruption stages of the second molar have a basic qualitative and quantitative effect on the distalization of the first molars because a tooth bud acts on the mesial neighboring tooth as a fulcrum.²⁸ On the contrary, some authors have reported that the presence and the position of second molars do not influence the amount and the type of maxillary first molar distalization.²⁹⁻³¹

Unilateral distalization has the theoretical advantage of stronger anchorage because the whole contralateral side is incorporated in the anchorage unit. In this study anchorage loss was apparent in both sides of the arch.

The translation of the upper midline toward the contralateral side by more than 1 mm was a very interesting finding. It seems that the whole anterior anchorage unit was rotated toward the contralateral side with the contralateral first molar as the center of rotation (Figure 3). It is interesting to compare these results with the results of an analogous study investigating the bilateral upper first and second molar distalization with a jig-type intraoral appliance.²³ Unilateral distalization seems to be associated with less anchorage loss and less tipping of the molar than bilateral distalization. This may be due to the size of the anchorage unit and the point of force application (at approximately the level of the molar's center of resistance) in the case of the appliance we used for the unilateral molar distalization. The differences are not very large, but in this unilateral study, the contralateral first molars were also part of the anchorage unit.

There is one preliminary study in the literature on

unilateral molar distalization with the Keles slider.³² The present investigation revealed more anchorage loss in comparison with that previous study, which used lateral cephalometric radiographs. This could be related not only to the different measurement approach but also to the differences in the anchorage unit size and design. In that previous study, the anchorage unit consisted of a Nance appliance, which covered the anterior part of the palate and the cingulum of the anterior teeth (anterior bite plane). An increased surface area in contact with the palatal mucosa and the anterior teeth might explain less anchorage loss.

Individual variation was an important finding of this investigation. The absence of contact points of the anchoring teeth, as in the case of ectopic canines, or irregularity between spaced or severely malaligned teeth probably diminished the capability of the anchorage unit to resist forward movement. Another factor that could partially explain individual variation is the anatomical characteristics of the palatal vault. Patients with insufficient seating of the Nance button because of a reduced palatal vault inclination might not be suitable candidates for noncompliance maxillary molar distalization.

It has been shown previously that the palatal rugae can be used as reference landmarks for the assessment of tooth movements.^{33–35} The zone of the palate along the midline raphe was also used because it significantly enhanced the reliability of the 3-D superimposition.³⁶ The previous studies using models to assess orthodontic movements used a photographic approach by projecting the rugae on the occlusal plane. This, unfortunately, implies a considerable methodological error because it depends entirely on the assumption that the occlusal plane remains unchanged, which is rarely the case. The use of a 3-D superimposition helps overcome these problems.

In this study, the zone of the palate along the midline raphe was also used because it has been shown to enhance the reliability of the whole procedure.³⁶ The superimposition area is thus a multiplanar surface with uniform relief characteristics clearly and easily defined in the three planes of space even in the case of partially missing information (eg, errors in the pouring technique or elastic deformation of the palatal rugae because of the Nance appliance). Further studies would be needed to compare the molar position at the end of distalization to its position at the end of the orthodontic treatment. On the basis of our clinical observations, we recommend a 2-month stabilization of the distalized molar to allow the distal drift of the premolars and canines of the ipsilateral side.

CONCLUSIONS

- The noncompliance intraoral appliance, Keles slider, was successful in achieving unilateral upper molar distalization into a Class I molar relationship in all cases under investigation. Close to parallel molar distalization was achieved on average.
- Anchorage loss accounted for half the space created between the first molar and the first premolar, but substantial variation was present among patients.
- Case selection is strongly recommended because significant anterior crowding, ectopic canines, or spacing can lead to significant anchorage loss.
- The advantage of the Keles slider is that it can be easily converted into a sort of Nance holding appliance at the end of molar distalization.

REFERENCES

1. Haack DC, Weinstein S. The mechanics of centric and eccentric cervical traction. *Am J Orthod.* 1958;44:236–257.
2. Baldini G. Unilateral headgear: lateral forces as unavoidable side effects. *Am J Orthod.* 1980;77:333–340.
3. Wohl TS, Bamonte E, Pearson HE. Nonextraction treatment of unilateral Class II, Division 1 malocclusion with asymmetric headgear. *Am J Orthod Dentofacial Orthop.* 1998;113:483–487.
4. Yoshida N, Jost-Brinkmann PG, Miethke RR, König M, Yamada Y. An experimental evaluation of effects and side effects of asymmetric face-bows in the light of in vivo measurements of initial tooth movements. *Am J Orthod Dentofacial Orthop.* 1998;113:558–566.
5. Clemmer EJ, Hayes EW. Patient cooperation in wearing orthodontic headgear. *Am J Orthod.* 1979;75:517–524.
6. Egolf RJ, BeGole EA, Upshaw HS. Factors associated with orthodontic patient compliance with intraoral elastic and headgear wear. *Am J Orthod Dentofacial Orthop.* 1990;97:336–348.
7. Zentner A. The problem of compliance in Orthodontics. In: Papadopoulos MA, ed. *Orthodontic Treatment for the Class II Non-compliant Patient: Current Principles and Techniques.* St Louis, Mo: Mosby; 2005. In press.
8. Papadopoulos MA. Overview of the inter-maxillary non-compliance appliances. In: Papadopoulos MA, ed. *Orthodontic Treatment for the Class II Non-compliant Patient: Current Principles and Techniques.* St Louis, Mo: Mosby; 2005. In press.
9. Bondemark L, Kuroi J, Bemhold M. Repelling magnets versus superelastic nickel-titanium coils in simultaneous distal movement of maxillary first and second molars. *Angle Orthod.* 1994;64:189–198.
10. Brickman CD, Sinha PK, Nanda RS. Evaluation of the Jones jig appliance for distal molar movement. *Am J Orthod Dentofacial Orthop.* 2000;118:49–53.
11. Haydar S, Uner O. Comparison of Jones jig molar distalization appliance with extraoral traction. *Am J Orthod Dentofacial Orthop.* 2000;117:49–53.
12. Bolla E, Muratore F, Carano A, Bowman SJ. Evaluation of maxillary molar distalization with the distal jet: a comparison with other contemporary methods. *Angle Orthod.* 2002;72:481–494.
13. Papadopoulos MA, Mavropoulos A, Karamouzou A. Cephalometric changes following simultaneous first and second

- maxillary molar distalization using a non-compliance intra-oral appliance. *J Orofac Orthop*. 2004;65:123–136.
14. Papadopoulos MA. Clinical efficacy of the non-compliance appliances used for Class II orthodontic correction. In: Papadopoulos MA, ed. *Orthodontic Treatment for the Class II Non-compliant Patient: Current Principles and Techniques*. St Louis, Mo: Mosby; 2005. In press.
 15. Reiner TJ. Modified Nance appliance for unilateral molar distalization. *J Clin Orthod*. 1992;26:402–404.
 16. Keles A. Unilateral distalization of a maxillary molar with sliding mechanics: a case report. *J Orthod*. 2002;29:97–100.
 17. Romeo A. Holograms in orthodontics: a universal system for the production, development, and illumination of holograms for the storage and analysis of dental casts. *Am J Orthod Dentofacial Orthop*. 1995;108:443–447.
 18. Kuroda T, Motohashi N, Tominanga R, Iwata K. Three-dimensional dental cast analyzing system using laser scanning. *Am J Orthod Dentofacial Orthop*. 1996;110:365–369.
 19. Motohashi N, Kuroda T. A 3-D computer-aided design system applied to diagnosis and treatment planning in orthodontics and orthognathic surgery. *Eur J Orthod*. 1999;21:263–274.
 20. Papadopoulos MA, Christou PK, Athanasiou AE, Boettcher P, Zeilhofer HF, Sader R, Papadopoulos NA. Three-dimensional craniofacial reconstruction imaging. *Oral Surg Oral Med Oral Pathol Oral Radiol Endod*. 2002;93:382–393.
 21. Hayashi K, Uechi J, Mizoguchi I. Three-dimensional analysis of dental casts based on a newly defined palatal reference plane. *Angle Orthod*. 2003;73:539–544.
 22. Quimby ML, Vig KWL, Rashid RG, Firestone AR. The accuracy and reliability of measurements made on computer-based digital models. *Angle Orthod*. 2004;74:298–303.
 23. Mavropoulos A, Karamouzou A, Kiliaridis S, Papadopoulos MA. Efficiency of noncompliance simultaneous first and second upper molar distalization: a three-dimensional tooth movement analysis. *Angle Orthod*. 2005;75:468–475.
 24. Dahlberg G. *Statistical Methods for Medical and Biological Students*. London, UK: Allen & Unwin; 1940:122–132.
 25. Gianelly AA, Bednar J, Dietz VS. Japanese NiTi coils used to move molars distally. *Am J Orthod Dentofacial Orthop*. 1991;99:564–566.
 26. Runge ME, Martin JT, Bukai F. Analysis of rapid maxillary molar distal movement without patient cooperation. *Am J Orthod Dentofacial Orthop*. 1999;15:153–157.
 27. Gulati S, Kharbanda OP, Parkash H. Dental and skeletal changes after intraoral molar distalization with sectional jig assembly. *Am J Orthod Dentofacial Orthop*. 1998;14:319–327.
 28. Kinzinger G, Fritz U, Diedrich P. Bipendulum and quad pendulum for non-compliance molar distalization in adult patients. *J Orofac Orthop*. 2002;63:154–162.
 29. Bussick TJ, McNamara JA Jr. Dentoalveolar and skeletal changes associated with the pendulum appliance. *Am J Orthod Dentofacial Orthop*. 2000;117:333–343.
 30. Byloff FK, Darendeliler MA. Distal molar movement using the pendulum appliance. Part 1: clinical and radiological evaluation. *Angle Orthod*. 1997;67:249–260.
 31. Muse DS, Fillman MJ, Emmerson WJ, et al. Molar and incisor changes with Wilson rapid molar distalization. *Am J Orthod Dentofacial Orthop*. 1993;104:556–565.
 32. Keles A. Maxillary unilateral molar distalization with sliding mechanics: a preliminary investigation. *Eur J Orthod*. 2001;23:507–515.
 33. Almeida MA, Phillips C, Kula K, Tulloch C. Stability of the palatal rugae as landmarks for analysis of dental casts. *Angle Orthod*. 1995;65:43–48.
 34. Bailey LT, Esmailnejad A, Almeida MA. Stability of the palatal rugae as landmarks for analysis of dental casts in extraction and nonextraction cases. *Angle Orthod*. 1996;66:73–78.
 35. Hoggan BR, Sadowsky C. The use of palatal rugae for the assessment of anteroposterior tooth movements. *Am J Orthod Dentofacial Orthop*. 2001;119:482–488.
 36. Miller RJ, Kuo E, Choi W. Validation of Align technology's treat III digital model superimposition tool and its case application. *Orthod Craniofac Res*. 2003;6(suppl. 1):143–149.