M3391-Ch19.qxd 11/14/05 5:47 PM Page 291

CHAPTER 19

The Keles slider appliance for bilateral and unilateral maxillary molar distalization

Ahmet Keles

CONTENTS

Introduction	291
Appliance construction	291
Bilateral distalization	292
Unilateral distalization	294
Keles jig	296
Conclusion	300

Introduction

Over the past decade, nonextraction treatment and noncompliance therapies have become more popular in correction of Class II malocclusions. Conventional treatment of Class II cases usually requires distal movement of maxillary molars in order to achieve a Class I molar and canine relationship. However, if the maxillary molars are not distalized bodily and adequate anchorage is not established to move premolars and canines distally, anchorage will be easily lost. The literature shows that various devices have been developed for molar distalization; headgear was used routinely for distal movement of maxillary molars.[1–3] However, headgear relies totally on patient cooperation, which could reduce treatment success and increase treatment duration.

The difficulties involved with headgear wear and dependence on patient cooperation stimulated many investigators to develop intraoral devices and techniques for distal movement of molars. Blechman & Smiley,[4] Gianelly et al,[5] and Bondemark & Kurol[6] used magnets for molar distalization. Gianelly et al[7] and Bondemark et al[8] used superelastic nickel-titanium (NiTi) coil springs for distal movement of maxillary molars.

In 1992, Hilgers developed the pendulum appliance for distal movement of molars.[9] The appliance consisted of beta-titanium alloy (TMA) springs and a button on the palate. Since 1996, numerous investigators have conducted studies on the pendulum appliance which demonstrated that the molars were distalized but that distal tipping also occurred.[10–13] The amount of tipping in these pendulum studies varied from 6.07° to 17.7°. Keles & Sayinsu developed the intraoral bodily molar distalizer (IBMD) for molar distalization.[14] The distalizing TMA (0.032 × 0.032″) spring design of the IBMD (Ormco, Orange, CA) was composed of two pieces that enabled bodily movement of molars. Their results showed that the molars distalized without tipping but anchorage loss also occurred.

The intraoral distalization appliances developed in the last decade of the 20th century eliminated the need for patient cooperation. However, distal tipping of molars and anchorage loss also occurred with most of these new devices.

In this chapter, the Keles slider (US Patent No: 6,626,665 B1) appliance will be introduced and its effectiveness assessed.

Appliance Construction

The maxillary first molars and first premolars are banded. Tubes of 0.045″ diameter are soldered to the palatal side of the Class II first molar bands. First premolar bands are attached to an acrylic Nance appliance with 0.040″ diameter stainless steel retaining wires (Fig. 19.1). The acrylic button also consists of an anterior bite plane. The purpose of creating an anterior bite plane is to disocclude the posterior teeth, enhance the molar distalization, and correct the anterior deep bite. On the palatal side of the molars, 0.040″ diameter stainless steel wires are embedded into the acrylic about 5 mm apical to the gingival margin of the first molars. These wires pass through the tube and are oriented parallel to the occlusal plane (Fig. 19.2). For molar distalization a heavy NiTi coil spring (2 cm long, 0.045″ diameter and 0.016″ thick) is placed between the lock on the wire and the tube, in full compression. The amount of force generated with the full compression of the 2 cm open coil is about 200 g. This force system allows consistent application of force at the level of the center of resistance of the first molars.

The biomechanics of the force system is presented in Figure 19.3. Patients are seen once a month and the screw is activated with the use of a special wrench. After the distalization, the appliance is removed and the molars are stabilized by a Nance appliance for

M3391-Ch19.qxd 11/14/05 5:47 PM Page 292

Figure 19.1 Occlusal view of the Keles slider.

Figure 19.2 Palatal view of the Keles slider.

2 months before the second phase of orthodontic treatment and maintained until the end of canine distalization. Currently, instead of fabricating the Nance appliance, the Keles slider can be converted to a Nance appliance by cutting the premolar retaining wires and removal of the anterior bite plane, which eliminates impression taking, model construction, and lab work. For better adaptation to the palate, the acrylic is relined at the chairside with light-cure acrylic Triad gel material (Dentsply, USA) (Figs 19.4–19.6).

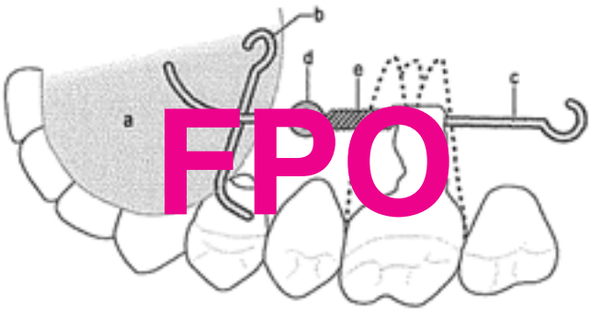

FPO

Figure 19.3 Biomechanics of the force system. Distal force is applied at the level of the center of resistance of the maxillary first molar. (a) Acrylic anterior bite plane. (b) Retaining wire for maxillary first premolar. (c) 0.040″ wire rod for distal sliding of maxillary first molar. (d) Adjustable screw for activation of the coil spring. (e) 0.040″ heavy NiTi open-coil spring. (f) Special tube soldered to the first molar band.

Figures 19.4–19.6 Chairside Nance construction from Keles slider. *(From Keles et al 2002,[17] with kind permission of Quintessence Publishing Co. Inc.)*

Bilateral Distalization

The cephalometric results of a preliminary investigation on 10 patients showed that the maxillary first molars were distalized bodily by an average of 4.1 mm.[15] Distal tipping and molar extrusion were not observed during distalization. A Class I molar relationship was achieved on average in a period of 5.5 months. The maxillary first premolars moved forward 2.7 mm, the incisors protruded 2.05 mm and proclined 3.45°. The overjet was increased 2.2 mm and the overbite was reduced by 1.9 mm on average. Another report related to bilateral distalization with the Keles slider with implant support showed that the molars moved distally with no anchorage loss. In fact, the first and second premolars drifted distally with the help of

M3391-Ch19.qxd 11/14/05 5:47 PM Page 293



Figure 19.5

Figure 19.7 Frontal intraoral views of patient 1 before distalization. *(From Keles et al 2002,[17] with kind permission of Quintessence Publishing Co. Inc.)*

Figure 19.6

Figure 19.8 Right intraoral view. *(From Keles et al 2002,[17] with kind permission of Quintessence Publishing Co. Inc.)*

transseptal fibers. The molars moved distally without tipping in a bodily fashion.[16]

Patient 1

PA was a female 19 years and 2 months old diagnosed with Class II, division 1 malocclusion.[17] Her primary complaint involved the buccally positioned maxillary canines. Dentally, she had a full cusp Class II molar and canine relationship with 7 mm of maxillary crowding (Figs 19.7–19.11). There was 80% overbite and 3 mm overjet. She had large restorations and hypersensitivity of the maxillary second molars; maxillary third molars were unerupted.

The treatment plan included extraction of the maxillary second molars and distalization of the first molars. The Keles slider was cemented in place (see Fig. 19.11). Following 7 months of treatment, the maxillary molars had distalized 5 mm on the right side and 6 mm on the left side, with each side achieving a super Class I molar relationship (Figs 19.12 and 19.13). There was 1 mm anchorage loss for the right first premolar and 2 mm anchorage loss for the left first premolar. The maxillary second premolars had drifted distally, with

M3391-Ch19.qxd 11/14/05 5:47 PM Page 294

Figure 19.9 Left intraoral view. *(From Keles et al 2002,[17] with kind permission of Quintessence Publishing Co. Inc.)*

Figure 19.11 Occlusal view after cementation of the Keles slider (maxillary second molars have been extracted). *(From Keles et al 2002,[17] with kind permission of Quintessence Publishing Co. Inc.)*

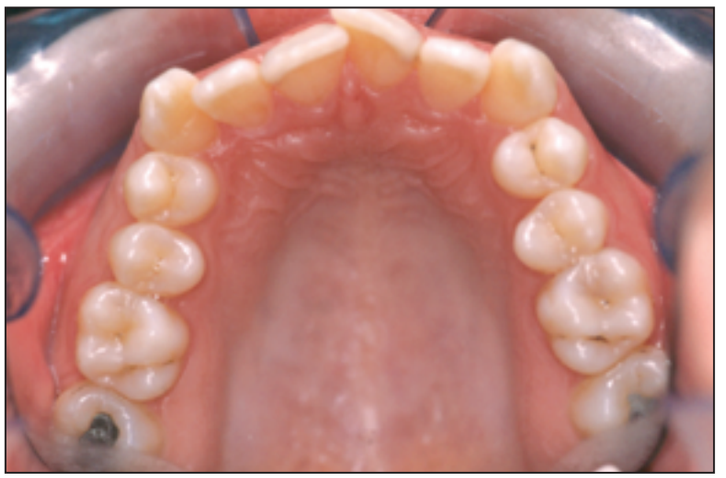

Figure 19.10 Occlusal intraoral view. *(From Keles et al 2002,[17] with kind permission of Quintessence Publishing Co. Inc.)*

Figure 19.12 Right intraoral view of patient 1 after removal of the Keles slider. *(From Keles et al 2002,[17] with kind permission of Quintessence Publishing Co. Inc.)*

the help of the transseptal fibers. Maxillary incisors had slightly proclined. A Nance appliance was cemented immediately after removal of the Keles slider and was maintained for 2 months to prevent mesial relapse of molars.

Two months later, during the Nance stabilization period, the first premolars and the canines had drifted distally to their initial position (Figs 19.14 and 19.15). Therefore anterior crowding was relieved. The molars were distalized in a parallel fashion and the maxillary third molars were erupting without any difficulty (Fig. 19.16). Anterior deep bite was corrected with the help of the anterior bite plane. Class I molar and canine relationships were achieved on both sides at the end of orthodontic treatment, overbite was reduced to 20%, and overjet was reduced to 2 mm (Figs 19.17–19.20). The maxillary third molars erupted without any difficulty. The patient's smile was improved and her straight profile was maintained.

Unilateral Distalization

The cephalometric results of a preliminary investigation showed that the maxillary first molars were distalized bodily on average 4.9 mm.[18] Distal tipping and molar extrusion were not observed during distalization. A Class I molar relationship was achieved on average in a period of 6.1 months. The maxillary first premolars moved forward

M3391-Ch19.qxd 11/14/05 5:47 PM Page 295

Figure 19.13 Left intraoral view. *(From Keles et al 2002,[17] with kind permission of Quintessence Publishing Co. Inc.)*

Figure 19.15 Left intraoral view. *(From Keles et al 2002,[17] with kind permission of Quintessence Publishing Co. Inc.)*

Figure 19.14 Right intraoral view of patient 1 at 2 months after removal of the Keles slider. The Class I molar relationship was maintained and distal drift of the first premolars and canines, as well as reduction of the overjet, was achieved without any mechanotherapy. *(From Keles et al 2002,[17] with kind permission of Quintessence Publishing Co. Inc.)*

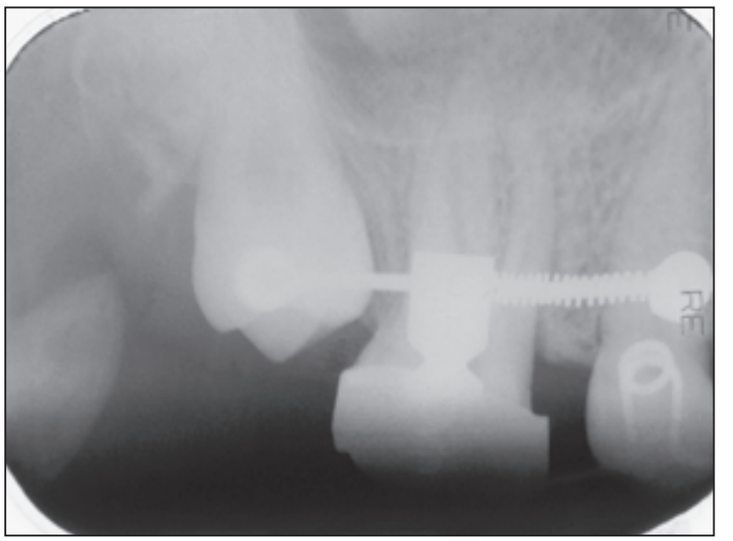

Figure 19.16 Periapical radiograph of patient 1 during distalization. Parallel distal migration of the first molars and the line of force application passing through the center of resistance of the first molars. *(From Keles et al 2002,[17] with kind permission of Quintessence Publishing Co. Inc.)*

bodily 1.3 mm, the incisors protruded 1.8 mm and proclined 3.2°. The overjet was increased 2.1 mm and the overbite was reduced by 3.12 mm on average.

Patient 2

OY was a female, 14 years 7 months of age, diagnosed as Class II, division 1 subdivision right malocclusion.[19] Dentally, she had 10% overbite, 3 mm overjet, and 4 mm maxillary midline left deviation. The maxillary canines were out of the arch and 9 mm crowding was present. The maxillary third molars were congenitally missing (Figs 19.21–19.24). A unilateral Keles slider was applied for the first phase of treatment to distalize the Class II molars into Class I (Fig. 19.25). Five months later we observed that the maxillary molars had distalized bodily 4 mm on the right side and a Class I molar relationship was maintained on the left side (Figs 19.26–19.29). The

M3391-Ch19.qxd 11/14/05 5:47 PM Page 296

Figure 19.17 Frontal intraoral view of patient 1 at the end of fixed orthodontic treatment.

Figure 19.19 Left intraoral view.

Figure 19.18 Right intraoral view.

Figure 19.20 Occlusal intraoral view.

maxillary second premolars had drifted distally with the help of the transseptal fibers. No anchorage loss on the first premolars was observed but the maxillary incisors were proclined and overjet was increased 2 mm. The molars were stabilized by a Nance button for 2 months before the fixed orthodontic treatment. Second-stage fixed bonded and banded treatment lasted 14 months and bands and brackets were removed at the end of fixed appliance therapy (Figs 19.30–19.33)

Keles Jig

To make clinical application of the appliance easier, a modification has been made. This jig design allows the clinician to fit the appliance at the chairside. The jig consists of a distalizing rod, 0.040″ stainless steel round wire with a ball tip, a lock (Rocky Mountain Orthodontics Co., USA) and 10 mm long NiTi heavy coil spring, and a 0.045″ tube

M3391-Ch19.qxd 11/14/05 5:47 PM Page 297

Figure 19.21 Frontal intraoral view of patient 2 before distalization.

Figure 19.22 Right intraoral view.

Figure 19.23 Left intraoral view.

Figure 19.24 Occlusal intraoral view.

Figure 19.25 After the appliance has been cemented (to make the cementation, the lock is placed on the distal of the tube and will be removed after cementation).

with wire extension which attaches to the cleat on the first molar bands (Fig. 19.34).

For the acrylic button construction, light-cure Triad acrylic gel material (Dentsply, USA) is applied at the chairside. The first premolars are attached with 0.040″ stainless steel round wire to the button. The steel rod of the jig is embedded into the acrylic about 5 mm apical to the gingival margin of the molars, passes through the tube and is oriented parallel to the occlusal plane.

M3391-Ch19.qxd 11/14/05 5:48 PM Page 298

Figure 19.26 Frontal intraoral view of patient 2 after removal of the Keles slider.

Figure 19.29 Occlusal intraoral view.

Figure 19.27 Right intraoral view.

Figure 19.30 Frontal intraoral view of patient 2 at the end of fixed orthodontic treatment.

Figure 19.28 Left intraoral view.

Figure 19.31 Right intraoral view.

M3391-Ch19.qxd 11/14/05 5:48 PM Page 299

Figure 19.32 Left intraoral view.

Figure 19.33 Occlusal intraoral view.

Figure 19.34 Keles jig (palatal view).

Figures 19.35–19.37 Stages in the chairside construction of the Keles slider.

Figures 19.36

This new method of application of the jig allows the chairside construction of a Keles slider without the need for laboratory construction. The construction stages are presented in Figures 19.35–19.37. The progress pictures of the first-phase treatment are presented in Figures 19.38–19.41.

After distalization is complete, the Keles slider is converted to s Nance holding appliance and distopalatal bends are made on the terminal ends of the wire connected to the tubes in order to derotate the molars if mesiobuccal rotations are needed (Figs 19.42–19.45).

M3391-Ch19.qxd 11/14/05 5:48 PM Page 300

Figure 19.37

Figure 19.39 One month later.

Figure 19.38 Patient 3: distal translation of first and second molars.. Initial occlusal photographs.

Figure 19.40 Three months later.

Conclusion

Our results show that the Keles slider is an effective appliance for the bodily distalization of molars. A Class I molar relationship can be established in a short period of time and there is little anchorage loss in comparison with other intraoral distalization mechanisms. The appliance is effective in deep bite correction with the help of the anterior bite plane accommodated to the Nance button. After the molar distalization is completed, the coil springs should be inactivated and the bite plane and the retaining wires for the first premolars should be removed from the appliance and should be kept in the mouth for 2 months as a Nance appliance. Overcorrection and stabilization of molars by converting the device into a passive holding

M3391-Ch19.qxd 11/14/05 5:48 PM Page 301

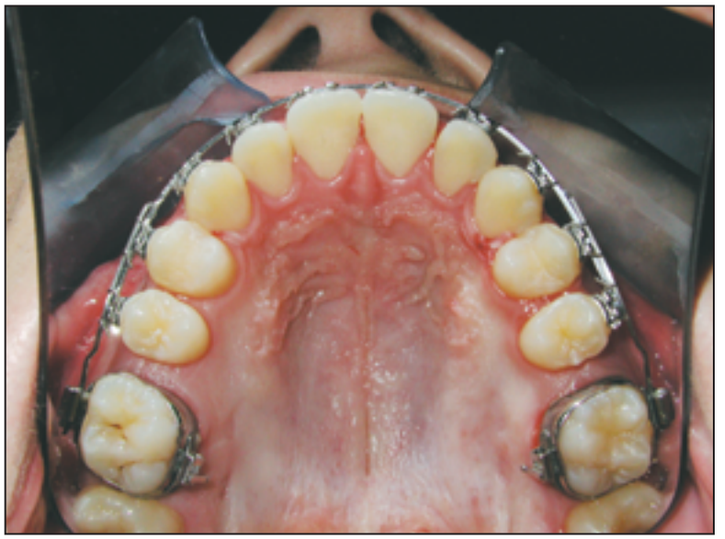

Figure 19.41 Four months later.

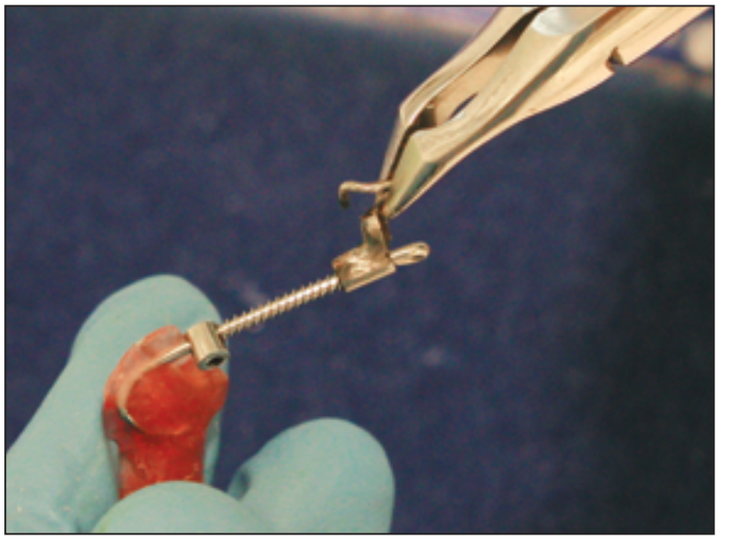

Figure 19.43

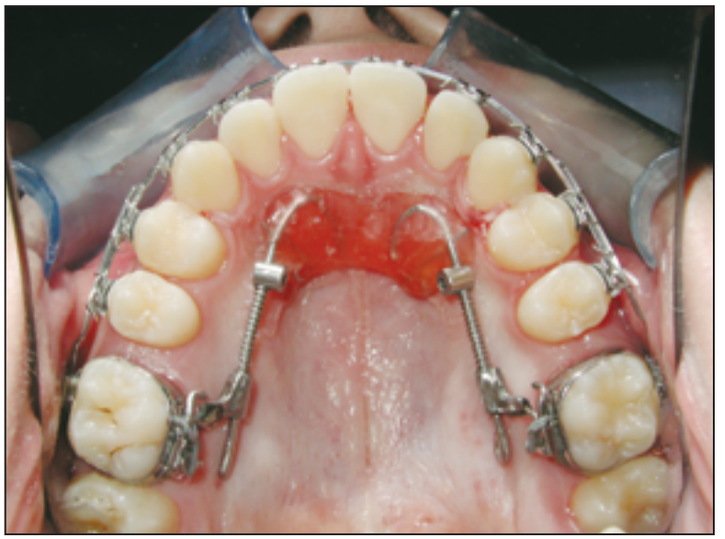

Figures 19.42–19.45 Conversion of Keles slider to anchorage appliance with anti-rotation bends to derotate the molars if further rotations are needed.

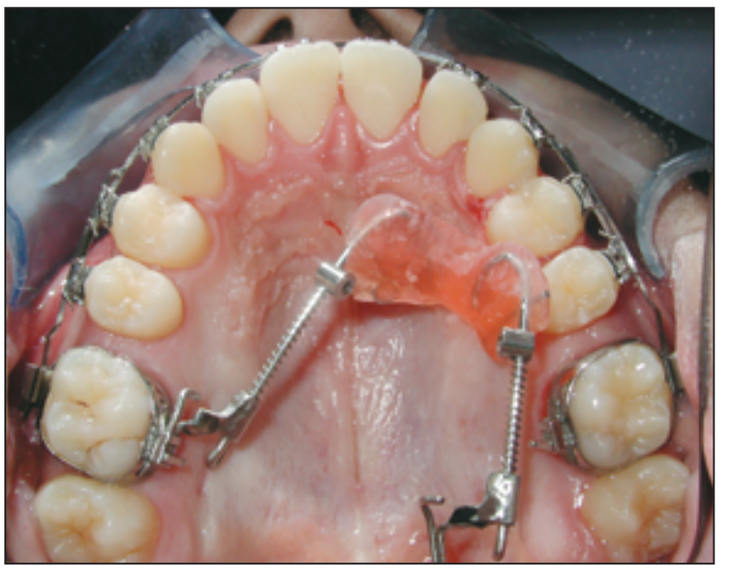

Figures 19.44

appliance for 2 months would allow the first premolars to drift distally to their initial position and allow some time for the newly formed and remodeled bone around the roots of the first molars to mineralize. When second-stage orthodontic treatment starts, the molars would provide good anchorage for canine distalization and anterior retraction.

Another advantage of this appliance compared is the ease of activation; chair time for activation is very short. The latest version with the new jig design enables the appliance to be constructed at the chairside. Guided consistent distal force at the level of the center of resistance allows the molars to slide distally without the problems of tipping, excessive anchorage loss, and questionable patient cooperation.

M3391-Ch19.qxd 11/14/05 5:48 PM Page 302

Figures 19.45

Newton's third law of action and reaction (equal and opposite forces) is applicable in the design of the Keles slider. A compressed coil spring applies distal force at the level of the center of resistance of the first molars which enables bodily distalization of molars (action principle). The reciprocal effect of the compressed coil spring applies mesial force at a higher level along the roots of the first premolars and anterior teeth. The support from the anterior aspect of the palate would reduce the mesial dental movement (reaction principle).

The Keles slider is effective in distalizing molars with intraarch mechanics and should not be misused in the correction of skeletal Class II. It can be used on patients with dental Class II malocclusion underlying a Class I skeletal pattern with minimum or no mandibular crowding. Third molars should be addressed and removed surgically if the patient is older than 15 years.

References

1. Poulton DR. The influence of extraoral traction. Am J Orthod 1967;53:8–18.
2. Cangialosi TJ, Meistrell ME Jr, Leung MA, Ko JY. Cephalometric appraisal of edgewise class II nonextraction treatment with extraoral force. Am J Orthod Dentofacial Orthop 1988;93: 315–324.
3. Arvystas MG. Nonextraction treatment of severe Class II, division 2 malocclusions. Part 2. Am J Orthod Dentofacial Orthop 1991;99:74–84.
4. Blechman AM, Smiley H. Magnetic force in orthodontics. Am J Orthod Dentofacial Orthop 1978;74:435–443.
5. Gianelly AA, Vaitas AS, Thomas WM, Berger DG. Distalization of molars with repelling magnets. J Clin Orthod 1988;22:40–44.
6. Bondemark L, Kurol J. Distalization of maxillary first and second molars simultaneously with repelling magnets. Eur J Orthod 1992;14:264–272.
7. Gianelly AA, Bednar J, Dietz VS. Japanese NiTi coils used to move molars distally. Am J Orthod Dentofacial Orthop 1991;99:564–566.
8. Bondemark L, Kurol J, Bernhold M. Repelling magnets versus superelastic nickel-titanium coils in simultaneous distal movement of maxillary first and second molars. Angle Orthod 1994;63:189–198.
9. Hilgers JJ. The pendulum appliance for Class II non-compliance therapy. J Clin Orthod 1992;26: 706–714.
10. Ghosh J, Nanda RS. Evaluation of an intraoral maxillary molar distalization technique. Am J Orthod Dentofacial Orthop 1996;110:639–646.
11. Byloff FK, Darendeliler MA, Clar E, Darendeliler A. Distal molar movement using the pendulum appliance. Part 2: The effect of maxillary molar root uprighting bends. Angle Orthod 1997;67: 261–270.
12. Bussick TJ, McNamara JA Jr. Dentoalveolar and skeletal changes associated with the pendulum appliance Am J Orthod Dentofacial Orthop 2000;117:333–343.
13. Joseph A, Butchart C. An evaluation of the pendulum distalizing appliance Semin Orthod 2000; 6:129–135.
14. Keles A, Sayinsu K. A New approach in maxillary molar distalization: intraoral bodily molar distalizer. Am J Orthod Dentofacial Orthop 2000;117: 39–48.
15. Tahir A. Cephalometric evaluation of Keles Slider appliance. Masters degree thesis. Istanbul: Marmara University; 2002.
16. Keles A, Erverdi N, Sezen S. Bodily molar distalization with absolute anchorage. Angle Orthod 2003;73:471–482.
17. Keles A, Pamukcu B, Cetinkaya E. Bilateral maxillary molar distalization with sliding mechanics: Keles Slider. World J Orthod 2002;3:57–66.
18. Keles A. Maxillary unilateral molar distalization with sliding mechanics: a preliminary investigation. Eur J Orthod 2001;23:507–515.
19. Keles A, Isguden B. Unilateral molar distalization with molar slider (two case reports). Turkish J Orthod 1999;12:193–202.